The Partogram
Episiotomy

Goal:

At the end of this lecture, each student should acquire complete knowledge, skills and positive attitude toward episiotomy and effect of this procedure in labor.

Objectives:

- **At the end of this lecture, each student will be able to:**
  - Define of episiotomy.
  - List purpose of episiotomy.

- Define indication of episiotomy.
- Discuss types of episiotomy.
- Discuss complication of episiotomy.
- List equipment of episiotomy.
- Know how to apply procedure of episiotomy.

Outlines:

- Introduction.
- Definition of episiotomy.
- Purpose of purpose of episiotomy.
- Indication of episiotomy.
- Types of episiotomy.
- Complication of episiotomy.
- Equipment of episiotomy (cutting -repair).
- Procedure of episiotomy.
- Video on episiotomy.

Introduction

Episiotomy, is a surgical incision made at the end of the second stage of labor to widen the vaginal opening, helps facilitate delivery. Ideally, an episiotomy relieves pressure on the perineum during difficult deliveries, resulting in an easily repairable incision when compared to uncontrolled vaginal trauma. The primary types of episiotomy are the midline (or median), which begins near the center of the perineum and extends straight downward, and the mediolateral, which starts similarly but angles 60 degrees to the side. Other less frequently used episiotomy incisions include the modified median, J-shaped.

Definition of episiotomy

- Episiotomy is a cut or (incision) through the area between vaginal opening and anus.
- This area is called the perineum.to wide vaginal opening and facilitate of delivery of head.

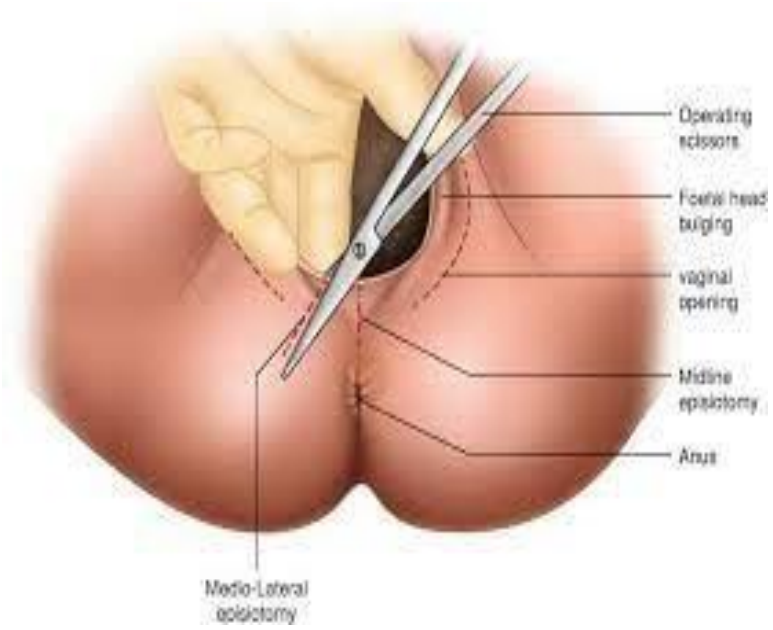

https://upload.wikimedia.org/wikipedia/commons/thumb/a/a0/Epiosotomy

Purpose of episiotomy:

1. To enlarge the vaginal introitus so as to facilitate easy and safe delivery of the fetus spontaneous or manipulative.
2. To minimize overstretching and rupture of the perineal muscles and fascia to reduce the stress and strain on the fetal head.
3. Reduces duration of the second stage, which may be important for maternal or fetal reasons.
4. Prevents tearing of the perineum. The clean and properly placed incisions are more properly heals than those a ragged one.

Indication of episiotomy

1. Fetal Distress

When the baby is showing signs of distress (e.g., abnormal fetal heart rate), episiotomy may be done to speed up delivery.

2. Shoulder Dystocia

When the baby's shoulders are stuck after the head is delivered, episiotomy provides more room for maneuvers to free the shoulders.

3. Instrumental Delivery

In cases of **forceps** or **vacuum-assisted delivery**, an episiotomy may be needed to allow the instruments to pass and reduce perineal trauma.

4. Rigid Perineum

In **first-time mothers** or when the perineum is not

stretching adequately, episiotomy may facilitate delivery and prevent severe natural tearing.

5. Large Baby (Macrosomia)

When the baby is expected to be large (usually >4000 grams), episiotomy may help avoid uncontrolled tears.

6. Breech Delivery

In breech vaginal deliveries, an episiotomy may be used to help deliver the after-coming head safely.

7. Prolonged Second Stage of Labor

When labor is not progressing, and delivery needs to be expedited, especially if the mother is exhausted or pushing is

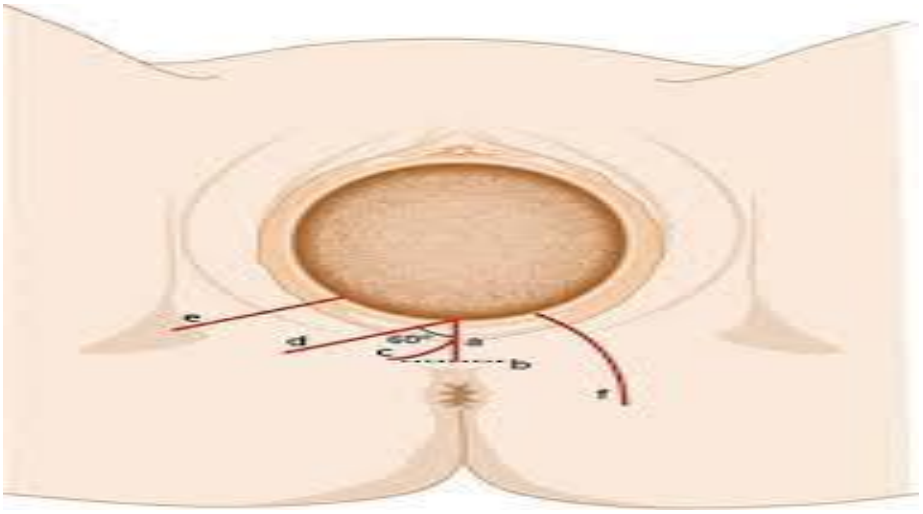

ineffective.

8. Preterm Delivery

In premature babies, episiotomy might reduce trauma to the baby during delivery by providing more space.

https://i0.wp.com/abdominalkey.com/wp-content/uploads/2017/08/A308966_1_En_6_Fig2_HTML.gif?w=960

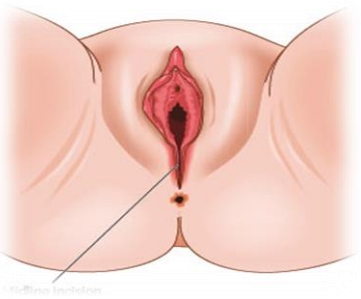

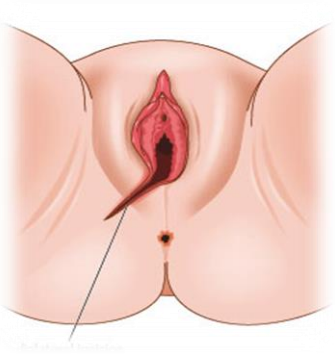

Types of Episiotomy

1. Median (Midline) Episiotomy:

Median: Incision made from the center of the fourchette and extends posteriorly along the midline for about 2.5 cm.

2. Mediolateral Episiotomy:

Mediolateral: Incision is made diagonally in a straight line from the midpoint of the fourchette either to the right or left about 2.5 cm away from the anus.

3. Lateral Episiotomy

Lateral: Incision starts 1 cm away from the center of the fourchette and extends laterally.

4. J-Shaped Episiotomy

"J" shaped: Incision begins in the center of the fourchette and is directed posteriorly along the midline for about1.5 cm and

then directed downwards and outwards along 5 or 7 0'clock position to avoid the anal sphincter.

https://nursekey.com/wp-content/uploads/2017/03/B9780443102523500158_gr1.jpg

Complication of episiotomy

A- Immediate (Early) Complications

1. **Excessive Bleeding**
   - ☞ From the incision site.
   - ☞ From vessels accidentally cut during the procedure.
2. **Infection (REEDA)**
   - ☞ The surgical wound may become infected, especially if hygiene is poor.
   - ☞ Signs: redness, swelling, pus, fever, foul-smelling discharge.
3. **Severe Pain**
   - ☞ Pain can be more intense and prolonged than natural perineal tears, requiring analgesics.
4. **Edema (Swelling)**
   - ☞ The perineum may become swollen due to trauma from the incision.

B- Late Complications

5. **Dyspareunia (Painful Intercourse)**
   - ☞ Due to scar tissue, tightness, or tenderness at the episiotomy site.
6. **Perineal Scar Formation**

- ☞ May cause discomfort, altered sensation, or cosmetic concerns.

7. Incontinence

- ☞ If the episiotomy extends to the anal sphincter, it may lead to fecal or gas incontinence, occurrence of fistula.

8. Chronic Perineal Pain

- ☞ Nerve damage or poorly healed tissue may result in persistent pain.

9. Psychological Effects

- ☞ Fear, anxiety, or trauma related to the birthing experience and episiotomy procedure.

Before procedure preparation of the mother

Physical preparation

1-Shave the perineum/ trim the hair as per the policy of the hospital during the first stage of labor, Episiotomy Giving and lidocaine.

2-Keep the mother in lithotomy or dorsal position with thigh flexed and separated.

3-Drape the mother to maintain privacy,

Psychological preparation

- Explain the procedure and its uses to the mother to win the confidence.
- Encourage and reassure during the procedure.

Preparation Equipment of episiotomy cutting and repair

A. For cutting Episiotomy-

- ☞ (Episiotomy scissors)
- ☞ Sterile gloves.
- ☞ Antiseptic solution (e.g., Betadine).

- Sterile drapes and gauze.
- Local anesthetic (e.g., Lidocaine 1%) and syringe.
- Prepare all labor equipment (four rings,2 arteries 4towels, etc.)

B. For Repairing Episiotomy:

- Needle holder.
- Tissue forceps.
- Absorbable sutures or non-absorbable sutures.
- Episiotomy catgut or silk) (0 or 1) suturing.
- Scissors, Sterile gauze and dressing,
- Additional anesthesia if needed.

Preparation of the Environment

1. Good source of light
2. Maintain privacy
3. Maintain sterile field

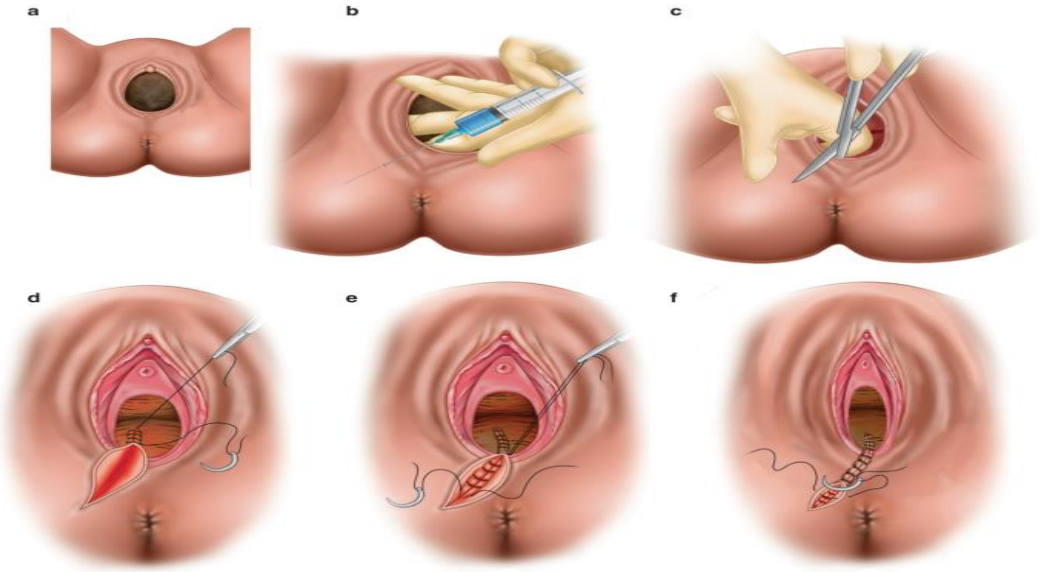

https://media.springernature.com/lw685/springer-static/image/chp%3A10.1007%2F978-3-030-85047-0_125/MediaObjects/209926_2_En_125_Fig2_HTML.png

Episiotomy

Action	Rational
1. Prepare the necessary equipment for episiotomy cutting and repair. 2. Check good light and placed complete all equipment. 3. Put mother in lithotomy position. 4. Explain what will happen to the mother to reassure her. 5. Up mothers' labor progress by vaginal examination (p.v).	
Episiotomy Steps- Making Incision 1. Infiltrate the local anesthesia into the perineum. 2. When the presenting part is distending the vulva during a contraction put the first two fingers of the left hand between the fetal presenting part and perineum to prevent injuring the fetal scalp. 3. Hold the syringe in the right hand; introduce the needle under the skin in the midline and at angle of 20% to intradermal skin. 4. Insert the needle for a distance of about 3 Cm. withdraw the plunger to ensure that the needle is not in vein, then slowly depress it while injecting 1-3 ml. of the solution.	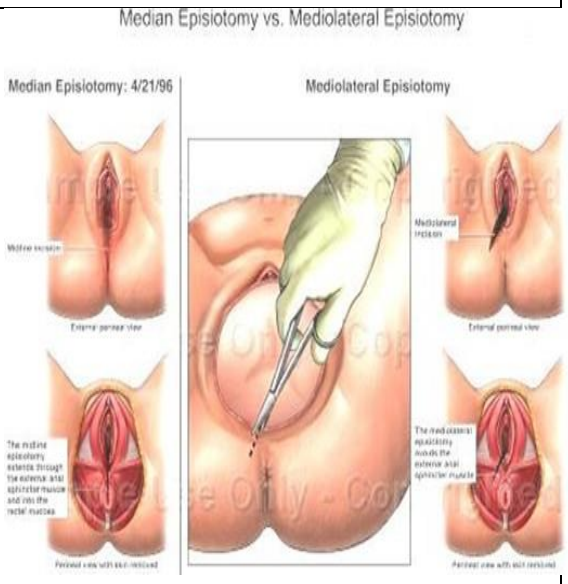

5. Then slowly withdraw the needle but don't remove it completely from the skin. 6. Redirect it, still within the perineum (the needle point is 1 Cm. to the right and inject a further 1-3 ml.). 7. Redirect the needle a third time to the left of the original site and infiltrate the remaining solution midline and at angle of 20% to the perineal skin. 8. Allow time for the local anesthesia (7 min.) to be effective. 9. Place two fingers between the fetal presenting part and the perineum when the fetal head is distending the vulva and perineum is stretched and is not retracting during contractions (because muscles are stretched so pain will be less) and making the incision with an episiotomy scissors, sharp blade of which is placed inside, in between the fingers and the posterior vaginal wall and the other on the skin. 10. Single clean cut (approximately 2.5 cm in length) is made in one of	

two directions: ☞ Median: extending directly from the lower vaginal border towards the anus ☞ Mediolateral: extending directly from the lower vaginal border towards the mother s' right or left. 11. If the woman has a previous episiotomy scar avoid incising the old scar as it doesn't heal well. 12. Replace the gloves with another sterile one (because the gloves used during second and third stages become desterilized. 13. Carefully examine for extensions and another tear and repair. 14. Make perineal care. 15. Cover the episiotomy incision with sterile dressing. 16. Change the towel under the mother.	
Repair of episiotomy	
1. Time of repair is done after expulsion of placenta 2. Insert a roll of swabs or a pack	

into the vagina. 3. Start suturing at the apex of the wound, close the vaginal tear with a continuous No.1 or zero catgut then suturing the mucosa then muscles with interapted suturing. (absorbable suture) 4. Close the skin over the muscles with interrupted suturing (No. 2 or 3 catgut). (absorbable suture) or nonabsorbable suture) 5. Inspect the wound, remove the vaginal pack. 6. Insert a finger into the rectum to exclude any involvement. 7. Clean the wound and cover it with a sterile pad.	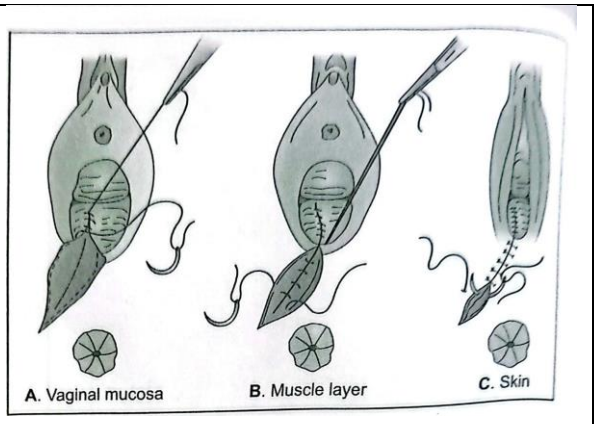
Post Procedure Tasks	
1. Make perineal care. 2. Swab with Betadine on the episiotomy site 3. Put a sterile dressing on the perineal area. 4. Remove all towels from the mother. 5. Wash hands after cleaning all instruments. 6. Report a complete information:	

7. Type and site of episiotomy. 8. Amount of bleeding. 9. If there are any abnormalities 10. Lift down the mother's legs and make her comfortable. 11. Clean, dry and repack the instrument 12. Rearrange the delivery trolley and the surrounding environment. 13. Give health teaching to the mother about care of 14. Episiotomy, complication diet, signs of infection.	

Episiotomy Checklist

Action	First Trial		Second Trial	
	Done	Note Done	Done	Note Done

6. Prepare the necessary equipment for episiotomy cutting and repair. 7. Check good light and placed complete all equipment. 8. Put mother in lithotomy position. 9. Explain what will happen to the mother to reassure her. 10. Up mothers' labor progress by vaginal examination (p.v).				
Episiotomy Steps- Making Incision 11. Infiltrate the local anesthesia into the perineum. 12. When the presenting part is distending the vulva during a contraction put the first two fingers of the left hand between the fetal presenting part and perineum to prevent injuring the fetal scalp. 13. Hold the syringe in the right hand; introduce the needle under the skin in the midline and at angle of 20% to intradermal skin. 14. Insert the needle for a distance of about 3 Cm. withdraw the plunger to ensure that the needle is not in vein, then slowly depress it while injecting 1-3 ml. of the solution. 15. Then slowly withdraw the needle but don't remove it completely from the skin. 16. Redirect it, still within the perineum (the needle point is 1 Cm. to the right and inject a further 1-3 ml.). 17. Redirect the needle a third time to the left of the original site and infiltrate the				

remaining solution midline and at angle of 20% to the perineal skin. 18. Allow time for the local anesthesia (7 min.) to be effective. 19. Place two fingers between the fetal presenting part and the perineum when the fetal head is distending the vulva and perineum is stretched and is not retracting during contractions (because muscles are stretched so pain will be less) and making the incision with an episiotomy scissors, sharp blade of which is placed inside, in between the fingers and the posterior vaginal wall and the other on the skin. 20. Single clean cut (approximately 2.5 cm in length) is made in one of two directions: ☞ Median: extending directly from the lower vaginal border towards the anus ☞ Mediolateral: extending directly from the lower vaginal border towards the mother s' right or left. 21. If the woman has a previous episiotomy scar avoid incising the old scar as it doesn't heal well. 22. Replace the gloves with another sterile one (because the gloves used during second and third stages become desterilized. 23. Carefully examine for extensions and another tear and repair. 24. Make perineal care. 25. Cover the episiotomy incision with sterile				

dressing. 26. Change the towel under the mother.				
Repair				
27. Time of repair is done after expulsion of placenta 28. Insert a roll of swabs or a pack into the vagina. 29. Start suturing at the apex of the wound, close the vaginal tear with a continuous No.1 or zero catgut then suturing the mucosa then muscles with interapted suturing. (absorbable suture) 30. Close the skin over the muscles with interrupted suturing (No. 2 or 3 catgut). (absorbable suture) or non-absorbable suture) 31. Inspect the wound, remove the vaginal pack. 32. Insert a finger into the rectum to exclude any involvement. 33. Clean the wound and cover it with a sterile pad.				
Post procedures				

34. Make perineal care. 35. Swab with Betadine on the episiotomy site 36. Put a sterile dressing on the perineal area. 37. Remove all towels from the mother. 38. Wash hands after cleaning all instruments. 39. Report a complete information: 40. Type and site of episiotomy. 41. Amount of bleeding. 42. If there are any abnormalities 43. Lift down the mother's legs andmake her comfortable. 44. Clean, dry and repack the instrument 45. Rearrange the delivery trolley and the surrounding environment. 46. Give health teaching to the mother about care of 47. Episiotomy, complication diet, signs of infection.				
Total score:				
Date:				

Student Name: **Instructor Name:**